

A modified approach to nail surgery

Nathaniel J. Jellinek, MD
Department of Dermatology

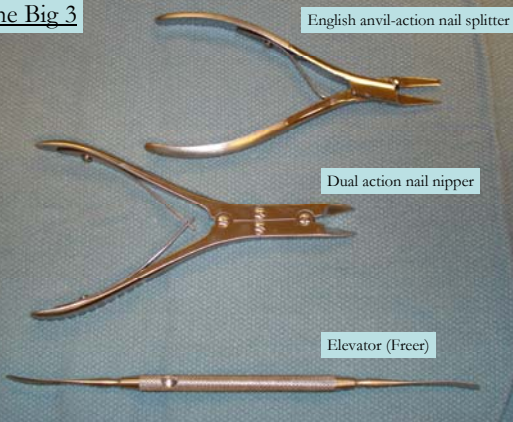


AAD Summer Meeting
8/08 - Chicago

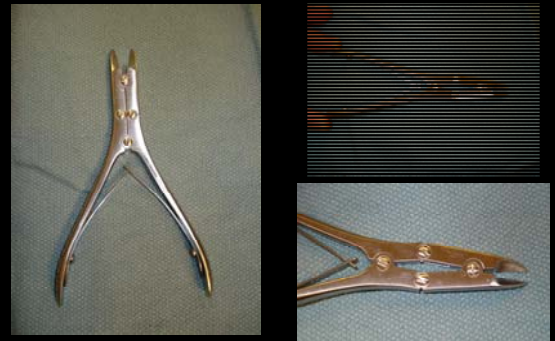

Nail Surgery Instruments

The Big 3



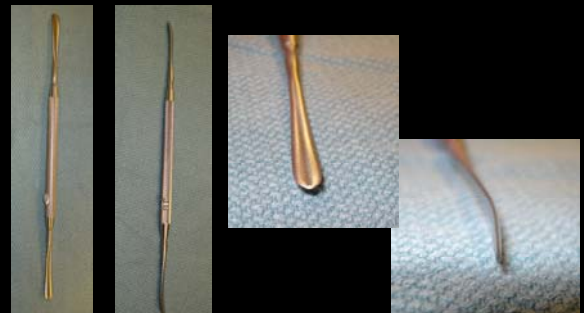Dual action nail nipper: spring action and “double jointed” system increases cutting force when trimming and paring thickened nails

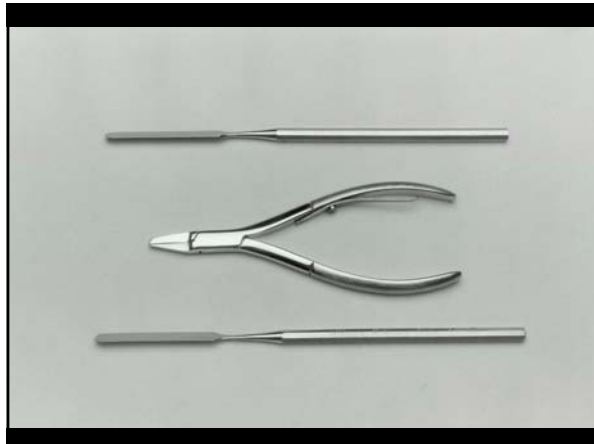


English anvil-action nail splitter: one cutting, tapered edge cuts onto a flat, anvil-like surface which fits under nail plate. Also has spring action system to increase force.



Elevator: fits between nail plate and nail bed/nail folds for avulsion/undermining. It comes in flexible or rigid models with narrow or wide spatula ends (Freer-double ended; Locke-flat, wide)



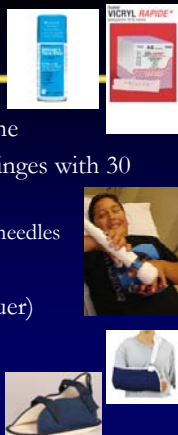


Nail surgery instruments

- Dual action nail nipper
- English anvil-action nail splitter
- Elevator
ALSO VERY HELPFUL
- Fine-tipped hemostat
- Gradle (or other fine-tipped tissue-cutting) scissors
- Tourniquet (glove with finger rolled up or 1 inch penrose drain or specialized instrument)
- Scalpel handle and blade (Teflon-coated is ideal for matrix)
- Skin hook(s), suturing kit
- +/- toothed forceps, electrosurgery instrument

Even more helpful extras

- Suture: Vicryl rapide, Vicryl, Prolene
- 1 and 3 ml tuberculin luer-lock syringes with 30 gauge needles
 - 0.3 ml insulin syringe with 31 gauge needles
- Massager
- Cryogen spray (Fluro-Ethyl, Gebauer)
- Arm slings
- Orthopedic open-toed cast boots

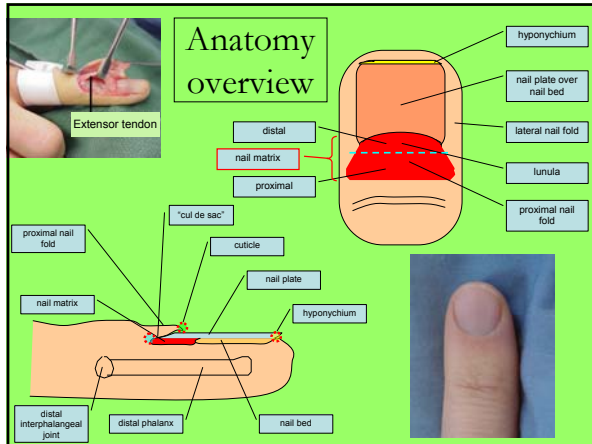


Approach to nail surgery

Almost every patient will be apprehensive about nail surgery.

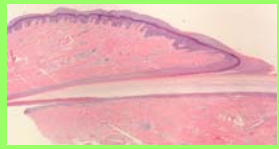
Keys to Success

- * Understand anatomy, histology, and pathology of nail unit.
- ** Achieve perfect anesthesia with minimal discomfort.
- * Achieve unimpeded exposure of nail apparatus
- * Approach nail surgery like surgery everywhere else – with respect and confidence.



Histology of the nail apparatus

- Includes
 - Nail folds (proximal x 1 & lateral x 2)
 - Cuticle complex
 - (cuticle, solehorn)
 - Nail matrix
 - Nail plate
 - Nail bed
 - Hyponychium, onychocorneal band, distal groove



General rules for nail surgery (I)

1. Photograph before surgery
2. Informed consent
3. Preoperative radiology when appropriate
4. Antibiotics?
5. Complete anesthesia
6. Postoperative instructions and analgesia
7. Personal availability
8. Follow-up

General rules for nail surgery (II)

1. Preoperative diagnosis
2. Exposure
 - Plate avulsion ✓
 - Nail fold reflection ✓
 - Bloodless field ✓
3. Choice/Variety of procedures

The choices are relatively simple once you have good exposure.

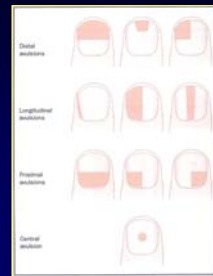
Traditional teaching:

Nail plate avulsion

Distal
Proximal

More current approach: Nail plate avulsion

- Distal
- Proximal



- Distal
- Proximal
- Curl*
- Trap door
- Partial
 - Lateral
 - Longitudinal
 - Proximal*
 - Central
 - Distal
 - Quadrant
- Replace the avulsed nail

Albrechte P, Dumontier G. Basic and advanced nail surgery (Part I: Principles and Techniques). In Selzer RC, Daniel CR III. *Nails: Diagnosis, Therapy, Surgery*. 2nd Edition. WB Saunders 2006.

* Requires proximal nail fold reflection

Exposure

- Nail plate avulsion ✓
- Bloodless field ✓
- Nail fold reflection ✓

The operative choices
are relatively simple
once you have good
exposure.